

Role of tubal surgery in the era of assisted reproductive technology: a committee opinion

The Practice Committee of the American Society for Reproductive Medicine
American Society for Reproductive Medicine, Birmingham, Alabama

This document reviews surgical options for achieving patency in obstructed fallopian tubes and the factors that must be considered when deciding between surgical repair and IVF. This document replaces the document of the same name, last published in 2012 (Fertil Steril 2012;97:539–45). (Fertil Steril® 2015; ■: ■–■. ©2015 by American Society for Reproductive Medicine.)

Key Words: Fallopian tube, hydrosalpinx, sterilization reversal, tubal disease, infertility

Earn online CME credit related to this document at <http://www.asrm.org/elearn>

Discuss: You can discuss this article with its authors and with other ASRM members at <http://fertstertforum.com/asrmpraccom-tubal-surgery/>



Use your smartphone to scan this QR code and connect to the discussion forum for this article now.*

* Download a free QR code scanner by searching for "QR scanner" in your smartphone's app store or app marketplace.

Tubal disease accounts for 25%–35% of female factor infertility, with more than half of the cases due to salpingitis (1). In addition, large studies report that up to 20%–30% of women regret having a tubal ligation (2–4). Thus, there is a need to determine the optimal treatment methods for patients with tubal factor infertility. There are several surgical options for achieving patency in obstructed fallopian tubes, depending on the location of the blockage. This document reviews these procedures and the factors that must be considered when deciding between surgical repair and in vitro fertilization (IVF).

DIAGNOSIS

A history of ectopic pregnancy, pelvic inflammatory disease (PID), endometriosis, or prior pelvic surgery raises the index of suspicion for tubal factor infertility. For patients with no risk factors, a negative chlamydia antibody

test indicates that there is less than a 15% likelihood of tubal pathology (5). However, chlamydia antibody testing is limited by false positives from cross-reactivity with *Chlamydia pneumoniae* IgG and does not distinguish between remote and persistent infection, nor does it indicate whether the infection resulted in tubal damage (5). Therefore, hysterosalpingography (HSG) is the standard first-line test to evaluate tubal patency (6).

If HSG suggests patent tubes, tubal blockage is highly unlikely (7). However, in 60% of patients in whom HSG showed proximal tubal blockage, repeat HSG 1 month later showed tubal patency (8). A similar percentage of patients shown by HSG to have proximal tubal occlusion were found to have patent tubes on subsequent laparoscopy (7). In addition, 11 of 18 proximal tubes excised for blockage were found to be patent (9). Laparoscopy, considered the gold standard for determining tubal patency, is not perfect: one study

showed that 3% of patients with bilateral tubal occlusion subsequently conceived spontaneously (10). Hysterosalpingography also has a therapeutic effect, with higher fecundity rates reported for several months after the procedure (11). Sonohysterosalpingography and transvaginal hydrolaparoscopy with chromotubation are alternative methods for assessing tubal patency (12–14).

GENERAL CONSIDERATIONS

Many variables need to be taken into consideration when counseling patients with tubal infertility regarding corrective surgery or IVF. The age of the patient, ovarian reserve, prior fertility, number of children desired, site and extent of the tubal disease, presence of other infertility factors, experience of the surgeon, and success rates of the IVF program are the most important. Patient preference, religious beliefs, cost, and insurance reimbursement also figure into the equation. In addition, a semen analysis should be performed early in the infertility investigation as the results may influence the management decision between tubal surgery and IVF.

Received March 20, 2015; accepted March 23, 2015.

Reprint requests: Practice Committee of the American Society for Reproductive Medicine, 1209 Montgomery Hwy., Birmingham, Alabama 35216 (E-mail: ASRM@asrm.org).

Fertility and Sterility® Vol. ■, No. ■, ■ 2015 0015-0282/\$36.00

Copyright ©2015 American Society for Reproductive Medicine, Published by Elsevier Inc.
<http://dx.doi.org/10.1016/j.fertnstert.2015.03.032>

The most recent national assisted reproductive technology (ART) registry data from 2012 noted a 32.2% live-birth rate per cycle initiated in patients across all ages with tubal infertility, similar to the 29.4% rate overall (15). Meaningful success rates with the various tubal surgical procedures are largely lacking. Most of the published literature is from surgeons with the greatest expertise. Their results may not be generalizable to less skilled or experienced surgeons. Furthermore, the results of tubal surgery and IVF are not directly comparable because surgical success is reported as pregnancy rate per patient, whereas IVF success rates are per cycle. As a result, there are no adequate trials comparing pregnancy rates with tubal surgery vs. IVF (16).

The advantages and disadvantages of IVF and tubal surgery need to be reviewed with the patient to provide assistance in her decision making. The main advantages of IVF are good per-cycle success rates and the fact that it is less surgically invasive. Its disadvantages include cost (especially if more than one cycle is required), the need for frequent injections and monitoring for several weeks, and, most significantly, the risks of multiple pregnancy and ovarian hyperstimulation syndrome. Although perhaps not directly applicable to tubal factor infertility, IVF alone has been associated with a higher incidence of adverse perinatal outcomes in singleton infants, such as perinatal mortality, preterm delivery, low and very low birth weights, intrauterine growth restriction and congenital malformations (17–21).

The advantages of tubal surgery are that it is a one-time, usually minimally invasive outpatient procedure, and patients may attempt conception every month without further intervention and may conceive more than once. They also avoid the risks associated with IVF. The disadvantages are generalizable to surgeons with less skill and experience and include the risks for surgical complications, such as bleeding, infection, organ damage, and reaction to anesthesia. There is also postoperative discomfort during the short recovery phase. Although the risk of ectopic pregnancy is increased in patients having IVF for tubal disease, it is higher after tubal surgery. In addition, for some patients the success following tubal surgery may be significantly lower than for IVF. All of these factors need to be considered when choosing the appropriate treatment strategy. To optimize pregnancy rates and reduce the risks, only those surgeons facile and experienced in laparoscopic and/or microsurgical techniques should attempt to perform corrective tubal surgery. The ideal patient candidate for tubal surgery is young, has no other significant infertility factors, and has tubal anatomy that is amenable to repair.

PROCEDURES FOR PROXIMAL TUBAL BLOCKAGE

Proximal tubal blockage accounts for 10%–25% of tubal disease (1). It may be due to obstruction resulting from plugs of mucus and amorphous debris, to spasm of the uterotubal ostium, or to occlusion, which is a true anatomic blockage from fibrosis due to salpingitis isthmica nodosa (SIN), PID, or endometriosis. Unless the proximal blockage on HSG is clearly due to SIN, selective salpingography or tubal cannulation can be attempted.

Tubal cannulation is accomplished using a coaxial catheter system under fluoroscopic guidance or via hysteroscopy with laparoscopic confirmation. An outer catheter is directed to the uterotubal ostium, and a selective salpingogram is performed. If tubal blockage is confirmed, a small inner catheter with a flexible guide wire is advanced through the proximal tube. Before performing this procedure, there should be confirmation of normal distal tubal anatomy.

If the obstruction is not overcome by tubal cannulation with gentle pressure, a true anatomic occlusion is assumed and the procedure is terminated. Excision of the proximal tubes in cases of failed tubal cannulation revealed SIN, chronic salpingitis, or obliterative fibrosis in 93% of patients (22). In these cases, IVF is preferred to resection and microsurgical anastomosis. In vitro fertilization would also be the preferred treatment for proximal tubal blockage in older women and in the presence of a significant male factor. However, microsurgery may be considered after failed tubal cannulation if IVF is not an option for the patient, but it should be attempted only by those with appropriate training. Tubal implantation has been relegated to historic interest only, as it is associated with very low success rates and risk of cornual rupture in pregnancy.

A meta-analysis of studies treating patients with bilateral proximal tubal occlusion showed that the obstruction is relieved in approximately 85% of the tubes with tubal cannulation and that approximately half of the patients conceive (1). Approximately one-third of the opened tubes subsequently reocclude (1, 23). The incidence of tubal perforation during tubal cannulation has been reported to be 3%–11%, without any clinical consequences (1). The optimal treatment of unilateral proximal tubal occlusion has not been determined. One study reported similar pregnancy rates with controlled ovarian stimulation and IUI in patients with untreated unilateral proximal tubal occlusion and in those with unexplained infertility (24).

Although tubal patency rates are similar with both fluoroscopic and hysteroscopic techniques, a meta-analysis found that ongoing pregnancy rates are higher with hysteroscopic cannulation (Table 1). This finding may be due to the opportunity to diagnose and treat another pelvic pathology during laparoscopy or to the fact that cannulation under direct vision may be less traumatic. Because tubal cannulation is a minor procedure with results comparable to those of microsurgical resection and anastomosis, it should be the treatment of choice. In the setting of failed tubal cannulation, microsurgery may be considered if IVF is not an option.

SURGERY FOR DISTAL TUBAL DISEASE—GOOD PROGNOSIS

The decision to repair or remove fallopian tubes with distal disease is usually made intraoperatively based on the prognosis for an intrauterine pregnancy. Distal tubal disease includes hydrosalpinges and fimbrial phimosis. Hydrosalpinges are completely occluded, whereas fimbrial agglutination by adhesions results in a narrow phimotic tubal

TABLE 1

Comparison of pregnancy rates and outcomes after various techniques.

Studies	No. patients	Pregnancy (%) ^a	SAB (%) ^a	Ectopic (%) ^a	Ongoing (%) ^a
Microsurgical (n = 5)	175	58.9 (51.2–75)	6.8 (0–56)	12.6 (0–25)	47.4 (37.5–5)
Hysteroscopic (n = 4)	133	48.9 (29–71.4)	13.8 (0–6.7)	9.2 (0–5.9)	48.9 (29–57)
Fluoroscopic (n = 9)	482	21.4 (6.3–55)	17.5 (2.1–7.8)	12.6 (0–7.8)	15.6 (8.7–40)

Note: Reproduced from Honore et al. (1). SAB = spontaneous abortion.

^a Values are median (range).

Practice Committee of the ASRM. Tubal surgery. *Fertil Steril* 2015.

opening. Both conditions are usually due to PID but may also result from peritonitis of any cause or tubal damage from previous surgery. A good prognosis is associated with patients who have no more than limited filmy adnexal adhesions, mildly dilated tubes (<3 cm) with thin and pliable walls, and a lush endosalpinx with preservation of the mucosal folds (25). Peritubal adhesions from the above causes or endometriosis may impair the ability of intrinsically normal tubes to capture an oocyte by mechanically interfering with the anatomic relationship between the distal fallopian tube and the ovary. One study of 147 patients reported cumulative pregnancy rates of 40% at 12 months after adhesiolysis by laparotomy, vs. 8% in an untreated group (26).

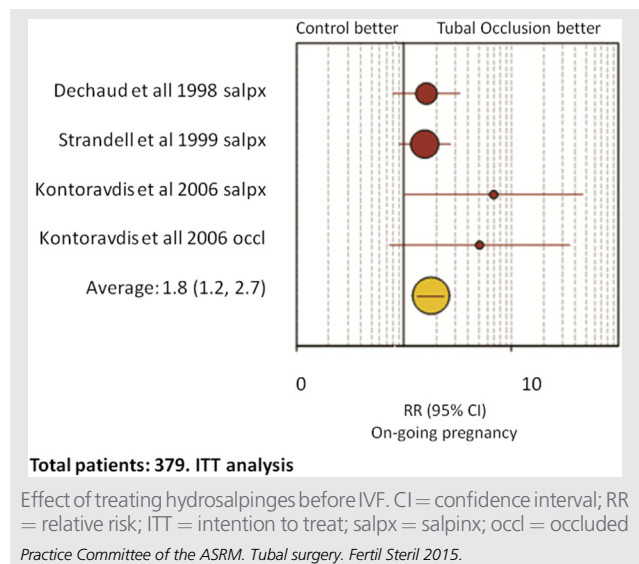
Laparoscopic neosalpingostomy and fimbrioplasty are carried out by opening a hydrosalpinx or increasing the opening for fimbrial phimosis, respectively. The fimbria are then everted and secured to the tubal serosa with sutures or electro-surgery (Bruhat procedure). Pregnancy rates after these procedures depend on the degree of tubal disease and are more favorable with good-prognosis patients (27, 28). Intrauterine and ectopic pregnancy rates after neosalpingostomy for mild hydrosalpinges range from 58% to 77% and from 2% to 8%, respectively (27). For severe disease, these values were 0%–22% and 0%–17%, respectively (27). Irreversible deciliation of the endosalpinx after an episode of salpingitis is responsible for the discrepancy between the patency rates and pregnancy rates after neosalpingostomy.

The fimbrioplasty procedure to open the tube more widely is virtually identical to neosalpingostomy. Neosalpingostomy and fimbrioplasty should be done only by laparoscopy, because the results are comparable to laparotomy, but with less risk (6, 29). Although IVF is preferred over salpingostomy for mild hydrosalpinges in older women and for those with male factor or other infertility factors, salpingostomy before IVF may improve the subsequent likelihood of success of IVF while still giving the patient the option to attempt spontaneous conception. Tuboplasty is not appropriate for women with severe disease or with both proximal and distal occlusion. Patients with poor-prognosis hydrosalpinges are better served by salpingectomy followed by IVF. Patients should be consented preoperatively for both salpingostomy as well as salpingectomy so the most appropriate procedure can be performed based on the extent of tubal disease. Postoperative reocclusion may occur, necessitating an additional surgical procedure to perform a salpingectomy or proximal tubal occlusion, as will be discussed.

SURGERY FOR DISTAL TUBAL BLOCKAGE—POOR PROGNOSIS

Patients having a poor prognosis may have extensive dense peritubal adhesions, massively dilated tubes with thick fibrotic walls, and/or sparse or absent luminal mucosa. Laparoscopic salpingectomy is indicated when the fallopian tube is damaged beyond repair by infection, endometriosis, or ectopic pregnancy. Numerous studies have shown that hydrosalpinges have a detrimental effect on IVF success rates. Two meta-analyses of these studies noted that the pregnancy, implantation, and delivery rates were approximately 50% lower and that the spontaneous abortion rate was higher in the presence of hydrosalpinges (30, 31). This finding may be due to mechanical flushing of the embryos from the uterine cavity, decreased endometrial receptivity, or a direct embryotoxic effect (32). Patients with hydrosalpinges visible on ultrasound may be more significantly affected (33, 34). Randomized clinical trials (RCTs) comparing pregnancy rates and outcomes with IVF for women with hydrosalpinges, with or without prior laparoscopic salpingectomy, reported that salpingectomy restores the rates of pregnancy and live birth to levels similar to those of women without hydrosalpinx (33, 35, 36) (Fig. 1). A Cochrane analysis

FIGURE 1



concluded that laparoscopic salpingectomy or occlusion should be considered before IVF for women with communicating hydrosalpinges (37). Even patients with a unilateral hydrosalpinx have been shown to have lower pregnancy rates with IVF (38, 39). Unilateral salpingectomy resulted in a significant improvement in IVF pregnancy rates in these patients (40). However, salpingectomies for bilateral hydrosalpinges yielded higher IVF pregnancy rates than for unilateral hydrosalpinges (33). There have been several case reports of spontaneous pregnancy after salpingectomy for a unilateral hydrosalpinx (33, 41–43). In the largest series of 25 patients, the mean duration of infertility was 3 years; 22 (88%) conceived spontaneously, within a mean of 5.6 months postoperatively with no ectopic pregnancies (43). Laparoscopic salpingectomy (or salpingostomy for favorable tubes) should be considered for patients with unilateral hydrosalpinges.

Laparoscopic salpingectomy is done by coagulating and dividing the proximal tube close to the cornua. The mesosalpinx is then serially coagulated and cut. It is prudent to stay close to the tube to avoid potentially compromising the ovarian blood supply.

Salpingectomy and even tubal ligation have been implicated as causes of subsequent diminished ovarian reserve. In one level 3 study, antral follicle counts and ovarian blood flow were reduced in the ipsilateral ovary after laparoscopic salpingectomy for ectopic pregnancy (44). However, another study of IVF before and after salpingectomy for ectopic pregnancy found no significant differences in dose or duration of gonadotropins used or peak estradiol levels. Furthermore, there was no difference in the number of oocytes retrieved or embryo quality between cycles or between the ovaries (45). Salpingectomy for hydrosalpinges also did not result in differences in ovarian stimulation or IVF parameters before or after surgery (46).

In two randomized, controlled trials (RCTs) researchers reported that proximal tubal occlusion was also effective in restoring IVF pregnancy rates in women with hydrosalpinx (36, 47). A study comparing proximal occlusion to salpingectomy for hydrosalpinx before IVF reported that follicle-stimulating (FSH) levels were increased from baseline after salpingectomy but not after proximal occlusion (48). Despite this finding, there were no differences in ovarian stimulation or IVF outcomes. Several studies found no compromise in ovarian reserve after laparoscopic tubal ligation by bipolar cautery (49, 50). An RCT found that tubal ligation by bipolar cautery had an adverse effect on ovarian volume and antral follicle counts, which was not seen with mechanical clips (51). Neither technique, however, was associated with changes in day-3 FSH, estradiol, inhibin-B, or antimüllerian hormone levels. Mechanical clips may be the preferred method for proximal occlusion. There is a theoretical concern that proximal occlusion may lead to an increase in the size of the hydrosalpinx, as the fluid can no longer drain through the uterus. For this reason, consideration may be given to widely fenestrating the hydrosalpinges at the time of proximal occlusion.

Proximal tubal occlusion for hydrosalpinges has also been accomplished hysteroscopically with Essure coil inserts,

but data on IVF success rates are limited to a few very small case series (52, 53). The trailing coils within the endometrial cavity may have the potential to act as an intrauterine contraceptive device, limiting embryo implantation with IVF. Complete tissue encapsulation of the Essure coils was observed by hysteroscopy in only 17% of patients within 1 year after placement and in 25% after 13–43 months (54). It is unknown whether tissue encapsulation confers a better prognosis for pregnancy.

Ultrasound-guided aspiration of hydrosalpinges at the time of oocyte retrieval yielded conflicting results in two small retrospective studies (55, 56). A randomized study comparing ultrasound-guided aspiration with a nontreated control reported significantly higher clinical pregnancy rates with aspiration (57). Intuitively, it makes sense that laparoscopic neosalpingostomy before IVF should improve the pregnancy rate, but there are still no confirmatory studies.

SURGERY FOR STERILIZATION REVERSAL

In patients with a prior tubal ligation the decision regarding whether to undergo tubal anastomosis or IVF should take into consideration the pros and cons of each treatment option for that individual couple. These patients are usually otherwise fertile and have better success rates after surgery than patients with tubal pathology. They may also have a better prognosis with IVF as well. Reversal of tubal ligation is achieved by opening the occluded ends of the proximal and distal segments and anastomosing them with fine nonreactive sutures using magnification and microsurgical techniques.

Traditionally, tubal anastomosis has been done via a full laparotomy incision with an overnight hospitalization, although it can be accomplished by minilaparotomy as an outpatient procedure. The few published reports of laparoscopic tubal anastomosis noted comparable pregnancy rates, but the procedure times tended to be prolonged (58, 59). The laparoscopic procedures were done in an identical fashion to open microsurgical tubal anastomosis. Only surgeons who are very facile with laparoscopic suturing and who have extensive training in conventional tubal microsurgery should attempt this procedure. Laparoscopic microsurgery is technically demanding and is best accomplished by those with the requisite training and experience. Recently, robotic technology has been used to facilitate laparoscopic tubal anastomosis, but further studies are needed to evaluate the risks and benefits and cost-effectiveness of this procedure.

The use of a one-stitch technique, titanium clips, and fibrin glue have been tried to circumvent the difficult suturing involved in laparoscopy. The goal of laparoscopic surgery should be to duplicate the standard open procedure as such shortcuts may compromise the clinical results. Robotic assistance has been evaluated as a means to facilitate laparoscopic tubal anastomosis. Two small trials comparing robotic to open tubal anastomosis reported that the da Vinci robot significantly increased operative times and cost with similar pregnancy rates, although recovery times were shorter (60, 61).

When considering tubal anastomosis, the woman's age is the most important prognostic factor (59, 62, 63). In women

younger than 40 years of age, the cumulative intrauterine pregnancy rate at 2 years is 70% using non-microsurgical technique, compared with more than 90% after microsurgical reversal of tubal sterilization (64). Even in women 40–45 years old, cumulative intrauterine pregnancy rates of 41.7%–70.6% have been reported (58, 62–66). Isthmic-isthmic repairs and longer final tubal lengths are generally thought to yield higher success rates, although this is not a universal finding. The rate of ectopic pregnancy after the procedure is 2%–10%, vs. 2% for IVF (15, 58–65). Tubal anastomosis should not be considered when the final tubal length is <4 cm, there are significant tubo-ovarian adhesions or stage 3–4 endometriosis, and/or there is more than a mild male factor.

A retrospective cohort study comparing IVF with tubal anastomosis reported that tubal anastomosis had a significantly higher cumulative pregnancy rate for women younger than 37 years of age, but there was no significant difference in women aged 37 years or older (67). In addition, the average cost per delivery for tubal anastomosis was almost half that for IVF (67). The decision regarding whether to have tubal anastomosis or IVF is left up to the patient, after reviewing the pros and cons of each treatment option.

SUMMARY

- Factors to be considered when counseling patients with tubal infertility regarding corrective surgery or IVF include the age of the woman and ovarian reserve, the number and quality of sperm in the ejaculate, the number of children desired, the site and extent of tubal disease, the presence of other infertility factors, the risk of ectopic pregnancy and other complications, the experience of the surgeon, the success rates of the IVF program, cost, and patient preference.
- There are no adequate trials comparing pregnancy rates with tubal surgery vs. IVF. However, IVF has a higher per-cycle pregnancy rate. Tubal anastomosis for reversal of tubal sterilization has a significantly higher cumulative pregnancy rate than IVF, and it is more cost efficient, even in women 40 years of age or older.
- Laparoscopic salpingectomy or proximal tubal ligation overcomes the detrimental effect of hydrosalpinges on IVF pregnancy rates in patients who are not candidates for corrective tubal surgery.

CONCLUSION

- There is good evidence to support HSG as the standard first-line test to assess tubal patency, but it is limited by false-positive diagnoses of proximal tubal blockage.
- The evidence is fair to recommend tubal cannulation for proximal tubal obstruction in young women with no other significant infertility factors.
- The evidence is fair to recommend laparoscopic fimbrioplasty or neosalpingostomy for the treatment of mild hydrosalpinges in young women with no other significant infertility factors.

- There is good evidence for recommending laparoscopic salpingectomy or proximal tubal occlusion in cases of surgically irreparable hydrosalpinges to improve IVF pregnancy rates.
- There is good evidence to support the recommendation for microsurgical anastomosis for tubal ligation reversal.

Acknowledgments: This report was developed under the direction of the Practice Committee of the American Society for Reproductive Medicine as a service to its members and other practicing clinicians. Although this document reflects appropriate management of a problem encountered in the practice of reproductive medicine, it is not intended to be the only approved standard of practice or to dictate an exclusive course of treatment. Other plans of management may be appropriate, taking into account the needs of the individual patient, available resources, and institutional or clinical practice limitations. The Practice Committee and the Board of Directors of the American Society for Reproductive Medicine have approved this report.

The following members of the American Society for Reproductive Medicine Practice Committee participated in the development of this document. All Practice Committee members disclosed commercial and financial relationships with manufacturers or distributors of goods or services used to treat patients. Members of the committee who were found to have conflicts of interest based on the relationships disclosed did not participate in the discussion or development of this document.

Samantha Pfeifer, MD; Richard Reindollar, MD; Rebecca Sokol, MD; Clarisa Gracia, MD, MSCE; Robert Rebar, MD; Andrew La Barbera, PhD; Randall Odem, MD; Daniel Dumesic, MD; Margareta Pisarska, MD; Samantha Butts, MD; Eric Widra, MD; Gregory Fossum, MD; Jay Sandlow, MD; Mitchell Rosen, MD; Michael Vernon, PhD.

REFERENCES

1. Honore GM, Holden AE, Schenken RS. Pathophysiology and management of proximal tubal blockage. *Fertil Steril* 1999;5:785–95.
2. Borrero SB, Reeves MF, Schwarz EB, Bost JE, Creinin MD, Ibrahim SA. Race, insurance status, and desire for tubal sterilization reversal. *Fertil Steril* 2008; 90:272–7.
3. Schmidt JE, Hillis SD, Marchbanks PA, Jeng G, Peterson HB. Requesting information about and obtaining reversal after tubal sterilization: findings from the U.S. Collaborative Review of Sterilization. *Fertil Steril* 2000;74: 892–8.
4. Chi IC, Jones DB. Incidence, risk factors, and prevention of poststerilization regret in women: an updated international review from an epidemiological perspective. *Obstet Gynecol Surv* 1994;49:722–32.
5. den Hartog JE, Morre SA, Land JA. Chlamydia trachomatis-associated tubal factor subfertility: immunogenetic aspects and serological screening. *Hum Reprod Update* 2006;12:719–30.
6. The Practice Committee of the American Society for Reproductive Medicine. Optimal evaluation of the infertile female. *Fertil Steril* 2006;86:S264–7.
7. Evers JL, Land JA, Mol BW. Evidence-based medicine for diagnostic questions. *Semin Reprod Med* 2003;21:9–15.
8. Dessole S, Meloni GB, Capobianco G, Manzoni MA, Ambrosini G, Canalis GC. A second hysterosalpingography reduces the use of selective technique for treatment of a proximal tubal obstruction. *Fertil Steril* 2000; 73:1037–9.

9. Sulak PJ, Letterie GS, Coddington CC, Hayslip CC, Woodward JE, Klein TA. Histology of proximal tubal occlusion. *Fertil Steril* 1987;48:437.
10. Mol BW, Collins JA, Burrows EA, van der Veen F, Bossuyt PM. Comparison of hysterosalpingography and laparoscopy in predicting fertility outcome. *Hum Reprod* 1999;14:1237–42.
11. Johnson N, Vanderkerchove P, Lilford R, Harada T, Hughes E, Luttjeboer F, et al. Tubal flushing for subfertility. *Cochrane Database Syst Rev* 2009:CD003718.
12. Hamed HO, Shahin AY, Elsamman AM. Hysterosalpingo-contrast sonography versus radiographic hysterosalpingography in the evaluation of tubal patency. *Int J Gynecol Obstet* 2009;105:215–7.
13. Ahinko-Hakamaa KM, Huhtala H, Tinkanen H. Confirmation of tubal patency in hysterosalpingo-contrast sonography by transvaginal hydrolaparoscopy. *Acta Obstet Gynecol* 2009;88:286–90.
14. Catenacci M, Goldberg JM. Transvaginal hydrolaparoscopy. *Semin Reprod Med* 2011;29:95–100.
15. Society for Assisted Reproductive Technology. Clinic summary report. Available at: https://www.sartcorsonline.com/rptCSR_PublicMultYear.aspx?ClinicPKID=0. Accessed April 22, 2015.
16. Pandian Z, Akande VA, Harrild K, Bhattacharya S. Surgery for tubal infertility. *Cochrane Database Syst Rev* 2008:CD006415.
17. Hansen M, Bower C, Milne E, de Klerk N, Kurinczuk J. Assisted reproductive technologies and the risk of birth defects—a systematic review. *Hum Reprod* 2005;20:328–38.
18. McDonald SD, Murphy K, Beyene J, Ohlsson A. Perinatal outcomes of singleton pregnancies achieved by in vitro fertilization: a systematic review and meta-analysis. *J Obstet Gynaecol Can* 2005;27:449–59.
19. Jackson RA, Gibson KA, Wu YW, Croughan MS. Perinatal outcomes in singletons following in vitro fertilization: a meta-analysis. *Obstet Gynecol* 2004;103:551–63.
20. Källén B, Finnström O, Lindam A, Nilsson E, Nygren KG, Otterblad PO. Congenital malformations in infants born after in vitro fertilization in Sweden. *Birth Defects Res* 2010;88:137–43.
21. El-Chaar D, Yang Q, Gao J, Bottomley J, Leader A, Wen SW, et al. Risk of birth defects increased in pregnancies conceived by assisted human reproduction. *Fertil Steril* 2009;92:1557–61.
22. Letterie GS, Sakas EL. Histology of proximal tubal obstruction in cases of unsuccessful tubal canalization. *Fertil Steril* 1991;56:831–5.
23. Pinto AB, Hovsepian DM, Wattanakumtornkul S, Pilgram TK. Pregnancy outcomes after fallopian tube recanalization: oil-based versus water-soluble contrast agents. *J Vasc Interv Radiol* 2003;14:69–74.
24. Farhi J, Ben-Haroush A, Lande Y, Fisch B. Role of treatment with ovarian stimulation and intrauterine insemination in women with unilateral tubal occlusion diagnosed by hysterosalpingography. *Fertil Steril* 2007;88:396–400.
25. American Fertility Society. The American Fertility Society classifications of adnexal adhesions, distal tubal occlusion, tubal occlusion secondary to tubal ligation, tubal pregnancies, Mullerian anomalies and intrauterine adhesions. *Fertil Steril* 1988;49:944–55.
26. Tulandi T, Collins JA, Burrows E. Treatment-dependent and treatment-independent pregnancy among women with periadnexal adhesions. *Am J Obstet Gynecol* 1990;162:354–7.
27. Nackley AC, Muasher SJ. The significance of hydrosalpinx in in vitro fertilization. *Fertil Steril* 1998;69:373–84.
28. Milingos SD, Kallipolitis GK, Loutradis DC, Liapi AG, Hassan EA, Mavrommatis CG, et al. Laparoscopic treatment of hydrosalpinx: factors affecting pregnancy rates. *J Am Assoc Gynecol Laparosc* 2000;7:355–61.
29. Bontis JN, Theodoridis TD. Laparoscopic management of hydrosalpinx. *Ann NY Acad Sci* 2006;1092:199–210.
30. Zeyneloglu HB, Arici A, Olive D. Adverse effects of hydrosalpinx on pregnancy rates after in vitro fertilization—embryo transfer. *Fertil Steril* 1998;70:492–9.
31. Camus E, Poncelet C, Goffinet F, Wainer B, Meriet F, Nisand I, et al. Pregnancy rates after in-vitro fertilization in cases of tubal infertility with and without hydrosalpinx: a meta-analysis of published comparative studies. *Hum Reprod* 1999;14:1243–9.
32. Practice Committee of the American Society for Reproductive Medicine. Salpingectomy for hydrosalpinx prior to in vitro fertilization. *Fertil Steril* 2008;90:S66–8.
33. Strandell A, Lindhard A, Waldenstrom U, Thorburn J, Janson PO, Hamberger L. Hydrosalpinx and IVF outcome: a prospective, randomized multicentre trial in Scandinavia on salpingectomy prior to IVF. *Hum Reprod* 1999;14:2762–9.
34. de Wit W, Gowrising CJ, Kuik DJ, Lens JW, Schats R. Only hydrosalpinges visible on ultrasound are associated with reduced implantation and pregnancy rates after in-vitro fertilization. *Hum Reprod* 1998;13:1696–701.
35. Dechaud H, Daures JP, Arnal F, Humeau C, Hedon B. Does previous salpingectomy improve implantation and pregnancy rates in patients with severe tubal factor infertility who are undergoing in vitro fertilization? A pilot prospective randomized study. *Fertil Steril* 1998;69:1020–5.
36. Kontoravdis A, Makrakis E, Pantos K, Botsis D, Deligeorgiou E, Creatsas G. Proximal tubal occlusion and salpingectomy result in similar improvement in in vitro fertilization outcome in patients with hydrosalpinx. *Fertil Steril* 2006;86:1642–9.
37. Johnson N, van Voorst S, Sowter MC, Strandell A, Mol BW. Surgical treatment for tubal disease in women due to undergo in vitro fertilisation. *Cochrane Database Syst Rev* 2010:CD002125.
38. Kassabji M, Sims JA, Butlerb L, Muasher SJ. Reduced pregnancy outcome in patients with unilateral or bilateral hydrosalpinx after in vitro fertilization. *Eur J Obstet Gynecol Reprod Biol* 1994;56:129–32.
39. Murray DL, Sagoskin AW, Widra EA. The adverse effect of hydrosalpinges on in vitro fertilization pregnancy rates and the benefit of surgical correction. *Fertil Steril* 1998;69:41–5.
40. Shelton KE, Butler L, Toner JP, Oehninger S, Muasher SJ. Salpingectomy improves the pregnancy rate in in-vitro fertilization patients with hydrosalpinx. *Hum Reprod* 1996;11:523–5.
41. Choe J, Check JH. Salpingectomy for unilateral hydrosalpinx may improve in vivo fecundity. *Gynecol Obstet Invest* 1999;48:285–7.
42. Aboulghar MA, Mansour RT, Serour GI. Spontaneous intrauterine pregnancy following salpingectomy for a unilateral hydrosalpinx. *Hum Reprod* 2002;17:1099–100.
43. Sagoskin AW, Lessey BA, Mottla GL, Richter KS, Chetkowski RJ, Chang AS, et al. Salpingectomy or proximal tubal occlusion of unilateral hydrosalpinx increases the potential for spontaneous pregnancy. *Hum Reprod* 2003;18:2634–7.
44. Chan CC, Ng EH, Li CF, Ho PC. Impaired ovarian blood flow and reduced antral follicle count following laparoscopic salpingectomy for ectopic pregnancy. *Hum Reprod* 2003;18:2175–80.
45. Dar P, Sachs GS, Strassburger D, Bukovsky I, Arieli S. Ovarian function before and after salpingectomy in artificial reproductive technology patients. *Hum Reprod* 2000;15:142–4.
46. Strandell A, Lindhard A, Waldenstrom U, Thorburn J. Prophylactic salpingectomy does not impair the ovarian response in IVF treatment. *Hum Reprod* 2001;16:1135–9.
47. Stadtmauer LA, Riehl RM, Toma SK, Talbert LM. Cauterization of hydrosalpinges before in vitro fertilization is an effective surgical treatment associated with improved pregnancy rates. *Am J Obstet Gynecol* 2000;183:367–71.
48. Nakagawa K, Ohgi S, Nakashima A, Horikawa T, Irahara M, Saito H. Laparoscopic proximal tubal division can preserve ovarian reserve for infertility patients with hydrosalpinges. *J Obstet Gynaecol Res* 2008;34:1037–42.
49. Carmona F, Cristeobal P, Casamitjana R, Balasch J. Effect of tubal sterilization on ovarian follicular reserve and function. *Am J Obstet Gynecol* 2003;189:447–52.
50. Bulent Tiras M, Noyan V, Ozdemir H, Guner H, Yildiz A, Yildirim M. The changes in ovarian hormone levels and ovarian artery blood flow rate after laparoscopic tubal sterilization. *Eur J Obstet Gynecol Reprod Biol* 2001;99:219–21.
51. Goynumur G, Kayabasoglu F, Aydogdu S, Wetherilt L. The effect of tubal sterilization through electrocoagulation on the ovarian reserve. *Contraception* 2009;80:90–4.
52. Mijatovic V, Veersema S, Emanuel MH, Schats R, Hompes PG. Essure hysteroscopic tubal occlusion device for the treatment of hydrosalpinx prior to in vitro fertilization-embryo transfer in patients with a contraindication for laparoscopy. *Fertil Steril* 2010;93:1338–42.

53. Darwish AM, El Saman AM. Is there a role for hysteroscopic tubal occlusion of functionless hydrosalpinges prior to IVF/ICSI in modern practice? *Acta Obstet Gynecol Scand* 2007;86:1484–9.
54. Kerin JF, Munday D, Ritossa M, Rosen D. Tissue encapsulation of the proximal Essure micro-insert from the uterine cavity following hysteroscopic sterilization. *J Min Invas Gynecol* 2007;14:202–4.
55. Sowter MC, Akande VA, Williams JA, Hull MG. Is the outcome of in-vitro fertilization and embryo transfer treatment improved by spontaneous or surgical drainage of a hydrosalpinx? *Hum Reprod* 1997;12:2147–50.
56. Van Voorhis BJ, Sparks AE, Syrop CH, Stovall DW. Ultrasound-guided aspiration of hydrosalpinges is associated with improved pregnancy and implantation rates after in-vitro fertilization cycles. *Hum Reprod* 1998;13:736–9.
57. Hammadieh N, Coomarasamy A, Ola B, Papaioannou S, Afnan M, Sharif K. Ultrasound-guided hydrosalpinx aspiration during oocyte collection improves pregnancy outcome in IVF: a randomized controlled trial. *Hum Reprod* 2008;23:1113–7.
58. Yoon TK, Sung HR, Kang HG, Lee CN, Cha KY. Laparoscopic tubal anastomosis: fertility outcome in 202 cases. *Fertil Steril* 1999;72:1121–6.
59. Cha SH, Lee MH, Kim JH, Lee CN, Yoon TK, Cha KY. Fertility outcome after tubal anastomosis by laparoscopy and laparotomy. *J Am Assoc Gyn Laparosc* 2001;8:348–52.
60. Rodgers AK, Goldberg JM, Hammel JP, Falcone T. Tubal anastomosis by robotic compared with outpatient minilaparotomy. *Obstet Gynecol* 2007;109:1375–80.
61. Dharia Patel S, Steinkampf MP, Whitten SJ, Malizia BA. Robotic tubal anastomosis: surgical technique and cost effectiveness. *Fertil Steril* 2008;90:1175–9.
62. Gordts S, Campo R, Puttemans P, Gordts S. Clinical factors determining pregnancy outcome after microsurgical tubal reanastomosis. *Fertil Steril* 2009;92:1198–202.
63. Dubuisson JB, Chapron CL, Nos C, Morice P, Aubriot FX, Garnier P. Sterilization reversal: fertility results. *Hum Reprod* 1995;10:1145–51.
64. Kim JD, Kim KS, Doo JK, Rhyeu CH. A report on 387 cases of microsurgical tubal reversals. *Fertil Steril* 1997;68:875–80.
65. Trimpos-Kemper TC. Reversal of sterilization in women over 40 years of age: a multicenter survey in the Netherlands. *Fertil Steril* 1990;53:575–7.
66. Petrucco OM, Silber SJ, Chamberlain SL, Warnes GM, Davies M. Live birth following day surgery reversal of female sterilization in women older than 40 years: a realistic option in Australia? *Med J Aust* 2007;187:271–3.
67. Boeckxstaens A, Devroey P, Collins J, Tournaye H. Getting pregnant after tubal sterilization: surgical reversal or IVF? *Hum Reprod* 2007;22:2660–4.