

# Medical treatment of ectopic pregnancy: a committee opinion

The Practice Committee of the American Society for Reproductive Medicine

American Society for Reproductive Medicine, Birmingham, Alabama

Methotrexate, a folic acid antagonist, is an effective treatment for early unruptured ectopic pregnancy. Several treatment regimens are available. Methotrexate is more effective when used to treat ectopic pregnancies with lower human chorionic gonadotropin (hCG) levels. However, there is no consensus on a threshold value that best predicts success or failure. Methotrexate can be used to treat ectopic pregnancies that occur in cornual, cervical, and cesarean scar locations, and it does not adversely affect ovarian reserve or subsequent fertility. This document replaces the previous document of the same name, last published in 2008 (*Fertil Steril* 2008;90:S206–12). (*Fertil Steril*® 2013;100:638–44. ©2013 by American Society for Reproductive Medicine.)

Earn online CME credit related to this document at [www.asrm.org/elearn](http://www.asrm.org/elearn)

**Discuss:** You can discuss this article with its authors and with other ASRM members at <http://fertstertforum.com/goldsteinj-methotrexate-ectopic-pregnancy/>



Use your smartphone to scan this QR code and connect to the discussion forum for this article now.\*

\* Download a free QR code scanner by searching for "QR scanner" in your smartphone's app store or app marketplace.

**E**ctopic pregnancy is a significant cause of morbidity and mortality in the first trimester of pregnancy (1). Currently, a high index of suspicion, serial hormone assays, and transvaginal ultrasonography facilitate the diagnosis and treatment of ectopic pregnancy before rupture occurs. Early nonsurgical diagnosis and timely treatment have resulted in a dramatic decline in mortality due to ectopic pregnancy (1).

Treatment with methotrexate (MTX), a folic acid antagonist highly toxic to rapidly replicating tissues, achieves results comparable to surgery for the treatment of appropriately selected ectopic pregnancies and is used commonly (2). Many unruptured ectopic pregnancies can be managed with either surgery or methotrexate. Surgery is specifically indicated in cases of suspected tubal rupture and when MTX is contraindicated.

## PREVALENCE

There are more than 100,000 ectopic pregnancies reported per year in the

United States, but the actual number is almost certainly much greater because only cases managed surgically are reported (3, 4). At least 90% of all ectopic pregnancies are located in the fallopian tube, and 80% of those are located in the ampullary segment of the tube (5).

## RISK FACTORS

Any pregnant woman potentially can have an ectopic pregnancy. Damage to the fallopian tubes predisposes a woman to ectopic pregnancy. Knowledge of risk factors can help identify women who may benefit from close monitoring and early treatment. High-risk conditions include [1] previous ectopic pregnancy; [2] history of tubal surgery, including a previous tubal sterilization; [3] history of sexually transmitted infection, tubal infection, or pelvic adhesions; [4] current use of an intrauterine device; [5] conception resulting from assisted reproduction; [6] cigarette smoking; and [7] in utero exposure to diethylstilbestrol (6–8).

## DIAGNOSIS

Timely diagnosis of ectopic pregnancy is important to reduce risk of rupture and improve the success of medical management. Diagnosis of all women at risk for ectopic pregnancy should be prompt but is not always an emergency and should occur before rupture in a hemodynamically stable woman. Any woman of reproductive age experiencing abnormal vaginal bleeding with or without abdominal pain is at risk for ectopic pregnancy. Such women should be followed closely until a diagnosis is made. Given the high risk of recurrence, women with history of a previous ectopic pregnancy should be followed carefully, even in the absence of symptoms. For women who present in shock, immediate surgery is both diagnostic and therapeutic.

Diagnostic approaches that use serial human chorionic gonadotropin (hCG) assays, ultrasonographic examinations, and sometimes uterine curettage facilitate the early diagnosis of ectopic pregnancy (9–11). A gestational sac (or sacs) should become visible by transvaginal ultrasound between 5.5 and 6.0 weeks' gestational age (12, 13). In sequence, structures such as a gestational sac ("double decidual

Received June 6, 2013; accepted June 7, 2013; published online July 10, 2013.

No reprints will be available.

Correspondence: Practice Committee, American Society for Reproductive Medicine, 1209 Montgomery Hwy., Birmingham, Alabama 35216 (E-mail: [ASRM@asrm.org](mailto:ASRM@asrm.org)).

*Fertility and Sterility*® Vol. 100, No. 3, September 2013 0015-0282/\$36.00

Copyright ©2013 American Society for Reproductive Medicine, Published by Elsevier Inc. <http://dx.doi.org/10.1016/j.fertnstert.2013.06.013>

sign”), yolk sac, and fetal pole with later cardiac motion become visible by transvaginal ultrasound. When gestational age is not known, hCG levels can provide alternate criteria for timing and interpretation of transvaginal ultrasound (14, 15).

It is now accepted widely that with hCG levels above the hCG discriminatory zone of 1,500–2,500 IU/L, a normal intrauterine pregnancy (IUP), defined as a gestational sac, should be visible by transvaginal ultrasound. Thus, the absence of an intrauterine gestational sac when the hCG concentration is above the discriminatory zone implies an abnormal gestation. The specific cutoff value for the discriminatory zone used at each institution will depend on clinical expertise and the specific characteristics of the hCG assay used. A more conservative discriminatory zone, that is, a higher hCG level, may be used to minimize the risk of terminating a viable pregnancy (16). In the case of multiple pregnancy, hCG levels are higher at early stages of development than in singleton intrauterine gestations, but the rate of increase remains similar (17).

If the initial hCG level is below the discriminatory zone, and transvaginal ultrasound cannot definitively identify an intrauterine or extrauterine gestation, then serial hCG measurements are necessary to document either a growing, potentially viable, or a nonviable pregnancy. The minimum rise for a potentially viable pregnancy in women who present with symptoms of pain and/or vaginal bleeding is 53% every 2 days, based on the 99th percent confidence interval (CI) around the mean of the curve for hCG rise (up to 5,000 IU/L) over time (16). Previous data suggested that the minimum hCG rise is 66% over 2 days (18). However, on the basis of the newer data above, intervening with these criteria potentially may result in the interruption of viable pregnancies (18). When the hCG levels have risen above the discriminatory zone, ultrasound should be used to document the presence or absence of an IUP.

Declining hCG values suggest a failing pregnancy. Serial hCG levels can be used to show that the gestation is regressing spontaneously. After a complete miscarriage, hCG levels decline at least 21%–35% every 2 days, depending on the initial value (19). However, a decline in hCG concentrations at this rate, or faster, does not exclude entirely the possibility of a resolving ectopic pregnancy or its rupture.

The absence of a gestational sac with an hCG above the discriminatory zone or an abnormally rising or declining hCG level suggests an abnormal pregnancy but does not distinguish an ectopic pregnancy from a failed intrauterine gestation. The presumption of an ectopic pregnancy in such circumstances can be incorrect in up to 50% of cases (20). A uterine curettage and evaluation of uterine contents may be helpful in differentiating an abnormal IUP from an ectopic pregnancy (20). Limited endometrial biopsy, such as may be performed with an endometrial suction cannula or similar instrument, is insufficient to diagnose correctly the location of the pregnancy (21, 22). Alternatively, if hCG levels continue to rise after curettage, the diagnosis of ectopic pregnancy is established.

Effort should be made to diagnose ectopic pregnancy definitively before medical treatment with MTX. Medical

treatment for a suspected ectopic pregnancy without a definitive diagnosis does not reduce complication rates or cost because many women with undiagnosed miscarriage would otherwise be exposed to MTX and its side effects unnecessarily (20, 23). Potential consequences of medical management of a presumed ectopic pregnancy include the following: [1] subsequent pregnancies will be viewed as high risk for recurrent ectopic pregnancy resulting in repeated, costly, and anxiety-provoking diagnostic evaluations; [2] apparent efficacy of MTX to treat ectopic pregnancy will be artificially increased; and [3] an IUP may be exposed to a known teratogen and abortifacient (24–26). Exposure of a viable pregnancy to MTX may result in embryopathy, a very serious and avoidable complication that is being reported with increasing frequency (24).

## TREATMENT

Medical treatment protocols for MTX were established in the late 1980s and have become widely accepted as primary treatment for ectopic pregnancy (27–31). Methotrexate is a folic acid antagonist (26, 32). Folic acid normally is reduced to tetrahydrofolate by the enzyme dihydrofolate reductase (DHFR), a step in the synthesis of DNA and RNA precursors. Methotrexate inhibits DHFR, causing depletion of cofactors required for DNA and RNA synthesis. Folinic acid (leucovorin) is an antagonist to MTX that can help reduce otherwise prohibitive side effects, particularly when higher doses of MTX are used (26, 32).

Ideally, a candidate for medical management with MTX should meet the following criteria: [1] hemodynamic stability, [2] no severe or persistent abdominal pain, [3] commitment to follow-up until the ectopic pregnancy has resolved, and [4] normal baseline liver and renal function test results. Contraindications to MTX treatment are listed in Table 1.

Before the first dose of MTX, women should be screened with a complete blood count (CBC), liver function tests, serum creatinine, and blood type and Rh. Women having a history of pulmonary disease also should have a chest x-ray because of the risk of interstitial pneumonitis in patients with underlying lung disease. In addition, women must be advised to stop their prenatal vitamins that contain folic acid and any supplemental folic acid therapy because this will decrease the effectiveness of methotrexate.

There are two commonly used MTX treatment regimens: “multiple dose” and “single dose.” Schema for treatment and follow-up for the two regimens are summarized in Tables 2 and 3, respectively. The multiple-dose protocol is a regimen adapted from early experience with MTX treatment for trophoblastic disease and was the regimen first used to treat ectopic pregnancy (27, 28). The multiple-dose protocol alternates MTX (1 mg/kg) treatment with leucovorin (0.1 mg/kg) therapy. Methotrexate is continued until hCG falls by 15% from its peak concentration. Approximately 50% of patients so treated will not require the full 8-day regimen (29, 30). With the single-dose regimen, MTX is administered at a dose of 50 mg/m<sup>2</sup>. The term “single dose” actually is a misnomer because the regimen includes provisions for additional doses of MTX when the response is inadequate (33–35).

**TABLE 1****Contraindications to MTX therapy (25, 26, 29–31).****Absolute contraindications**

- Intrauterine pregnancy
- Evidence of immunodeficiency
- Moderate to severe anemia, leukopenia, or thrombocytopenia
- Sensitivity to MTX
- Active pulmonary disease
- Active peptic ulcer disease
- Clinically important hepatic dysfunction
- Clinically important renal dysfunction
- Breastfeeding
- Ruptured ectopic pregnancy
- Hemodynamically unstable patient

Note: MTX = methotrexate.

Practice Committee. Medical treatment of ectopic pregnancy. *Fertil Steril* 2013.

**Relative contraindications**

- Embryonic cardiac activity detected by transvaginal ultrasonography
- High initial hCG concentration (>5,000 mIU/mL)
- Ectopic pregnancy >4 cm in size as imaged by transvaginal ultrasonography
- Refusal to accept blood transfusion
- Inability to participate in follow-up

In both single- and multiple-dose MTX treatment protocols, once hCG levels have met the criteria for initial decline, hCG levels are followed serially at weekly intervals to ensure that concentrations decline steadily and become undetectable. Complete resolution of an ectopic pregnancy usually takes between 2 and 3 weeks but can take as long as 6 to 8 weeks when pretreatment hCG levels are in higher ranges (29, 30, 35). If declining hCG levels rise again, the diagnosis of a persistent ectopic pregnancy is made.

When the criteria described earlier are fulfilled, treatment with MTX yields treatment success rates comparable to those achieved with conservative surgery (2, 30, 31). Numerous open-label studies have been published demonstrating the efficacy of both MTX treatment regimens. One review concluded that MTX treatment was successful in 78%–96% of selected patients. Post-treatment hysterosalpingography documented tubal patency in 78% of cases; 65% of patients who attempted subsequent pregnancies succeeded, and the incidence of recurrent ectopic pregnancy was 13% (29, 31).

There have been no randomized trials directly comparing the two different MTX treatment protocols. In a meta-analysis

including data from 26 articles and 1,327 cases, the overall success rate for MTX treatment was 89% (35). The success rate of the multiple-dose regimen was 92.7% (95% CI, 89%–96%), which was statistically significantly higher than that achieved with the single-dose regimen (88.1%; 95% CI, 86%–90%) (35). After controlling for initial hCG values and the presence of embryonic cardiac activity, the failure rate for single-dose therapy was higher than that for multiple-dose treatment (odds ratio [OR] 4.75, 95% CI, 1.77–12.62) (33). A small, randomized clinical trial also noted that single-dose therapy has a higher failure rate, but the difference was smaller (relative risk [RR] 1.50; 95% CI, 0.44–5.01) (36). It is possible, but not established, that the difference in failure rates between the two protocols may not be as dramatic in women with an overall good prognosis for successful medical treatment.

A hybrid protocol, involving two equal doses of MTX (50 mg/m<sup>2</sup>) administered on days 1 and 4 without leucovorin rescue and follow-up as described previously for the single-dose protocol, may offer a more optimal balance between convenience and efficacy (37, 38). The protocol also allows

**TABLE 2****Multiple-dose MTX treatment protocol (28, 29).**

Treatment day	Laboratory evaluation	Intervention
Pretreatment	hCG, CBC with differential, liver function tests, creatinine, blood type, and antibody screen	Rule out spontaneous abortion RhoGAM if Rh negative
1	hCG	MTX 1.0 mg/kg IM LEU 0.1 mg/kg IM
2		
3	hCG	MTX 1.0 mg/kg IM if <15% decline day 1–day 3 If >15%, stop treatment and start surveillance LEU 0.1 mg/kg IM
4		
5	hCG	MTX 1.0 mg/kg IM if <15% decline day 3–day 5 If >15%, stop treatment and start surveillance LEU 0.1 mg/kg IM
6		
7	hCG	MTX 1.0 mg/kg IM if <15% decline day 5–day 7 If >15%, stop treatment and start surveillance LEU 0.1 mg/kg IM
8		

Note: Surveillance every 7 days (until hCG <5 mIU/mL). Screening laboratory studies should be repeated every week after the last dose of MTX. CBC = complete blood count; MTX = methotrexate; IM = intramuscularly; LEU = leucovorin.

Practice Committee. Medical treatment of ectopic pregnancy. *Fertil Steril* 2013.

TABLE 3

## Single-dose MTX treatment protocol (33).

Treatment day	Laboratory evaluation	Intervention
Pretreatment	hCG, CBC with differential, liver function tests, creatinine, blood type, and antibody screen	Rule out spontaneous abortion Rhogam if Rh negative MTX 50 mg/m <sup>2</sup> IM
1	hCG	
4	hCG	
7	hCG	MTX 50 mg/m <sup>2</sup> IM if $\beta$ -hCG decreased <15% between days 4 and 7

Note: CBC = complete blood count; MTX = methotrexate; IM = intramuscularly.

Practice Committee. Medical treatment of ectopic pregnancy. Fertil Steril 2013.

for more than two doses of MTX when hCG values do not decrease 15% between days 4 and 7.

Regardless of which protocol is used, physicians and patients should be aware of a number of important caveats when using MTX for the treatment of ectopic pregnancy (Table 4). Although some advocate waiting 3 months before allowing conception after treatment with MTX, there are no data addressing this issue. Potential concerns supporting a delay to conception include resolution of tubal edema from the ectopic and excretion of MTX.

### Predictors of MTX Failure

The most commonly identified predictors of MTX treatment failure are listed in Table 5. Whereas the prognosis for successful medical treatment has been demonstrated repeatedly to correlate with the initial hCG level, no consensus on a threshold value that best predicts success or failure has been established (39–42). One study noted that the failure rate of single-dose treatment was 13% (6 of 45) for initial hCG values between 5,000 IU/L and 9,999 IU/L, 18% (4 of 22) for concentrations between 10,000 IU/L and 14,999 IU/L, and 32% (7 of 22) when hCG values exceeded 15,000 IU/L (42). Another observed a 65% (9 of 17) failure rate for single-dose treatment with initial hCG levels above 4,000 IU/L (38), and still others have reported failure rates of 57% and of 62% when the initial hCG concentration is greater than 5,000 IU/L (40, 41). Analysis after combining all published data yields an OR for failure of 5.45 (95% CI, 3.04–9.78) when initial hCG values are above 5,000 IU/L compared with that observed when hCG concentrations are below that threshold. The failure rate for single-dose MTX treatment stratified by initial hCG

level is illustrated in Figure 1. Because the failure rate rises with the pretreatment hCG concentration, the single-dose MTX treatment regimen may be better reserved for patients with a relatively low initial hCG value (35, 40, 41).

### Treatment

Overall, MTX is a safe and effective treatment for an unruptured ectopic pregnancy. Very rarely, life-threatening complications have been reported with MTX (43, 44). More commonly encountered treatment and drug side effects associated with MTX are listed in Table 6. Some patients develop transient pain (“separation pain”) between 3 and 7 days after treatment begins (45), but such pain normally resolves within 4 to 12 hours of onset. When pain is severe and persistent, it is prudent to evaluate the patient’s vital signs and hematocrit, and if rupture is suspected, surgery should be performed.

Signs of treatment failure or suspected rupture are indications to abandon medical management and to proceed with surgical treatment. Signs suggesting treatment failure or possible rupture include hemodynamic instability; increasing abdominal pain, regardless of trends in hCG levels; and rapidly increasing hCG concentrations (>53% over 2 days) after 4 doses in the multi-dose regimen or after 2 doses in the single-dose regimen (46).

Serial ultrasonographic examinations after MTX treatment are unnecessary because ultrasonographic findings cannot demonstrate or predict treatment failure unless evidence of recent tubal rupture is observed (47). Ultrasound may be useful in the case of persistent pain, increasing hCG, or concern of tubal rupture.

TABLE 4

## Caveats for physicians and patients regarding the use of MTX (25, 26, 30, 31, 33, 44).

- Avoid intercourse until hCG is undetectable.
- Avoid pelvic examinations and ultrasound during surveillance of MTX therapy.
- Avoid sun exposure to limit risk of MTX dermatitis.
- Avoid foods and vitamins containing folic acid.
- Avoid gas-forming foods because they produce pain.
- Avoid new conception until hCG is undetectable.

Note: MTX = methotrexate, hCG = human chorionic gonadotropin.

Practice Committee. Medical treatment of ectopic pregnancy. Fertil Steril 2013.

TABLE 5

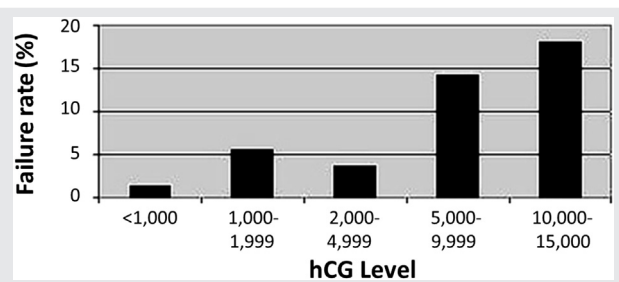
## Predictors of MTX treatment failure (38–41, 45).

- Adnexal fetal cardiac activity
- Size and volume of the gestational mass (>4 cm)
- High initial hCG concentration (>5,000 mIU/mL)
- Presence of free peritoneal blood
- Rapidly increasing hCG concentrations (>50%/48 h) before MTX
- Continued rapid rise in hCG concentrations during MTX

Note: MTX = methotrexate.

Practice Committee. Medical treatment of ectopic pregnancy. Fertil Steril 2013.

**FIGURE 1**



Single-dose MTX treatment failure based on hCG level. ASRM Practice Committee, Fertility and Sterility 2008, Medical Management of Ectopic Pregnancy.

Practice Committee. Medical treatment of ectopic pregnancy. *Fertil Steril* 2013.

### ADJUNCTIVE USE OF MTX

A persistent ectopic pregnancy can develop after salpingostomy or medical management. Consequently, it is important to monitor hCG levels until they become undetectable. When hCG levels rise or plateau, persistent trophoblastic tissue can be treated successfully with a single dose of MTX (47). Methotrexate also can be given immediately after salpingostomy as a prophylactic measure, especially in circumstances in which incomplete resection is more likely (48, 49). Risk for persistent ectopic pregnancy is increased in very early gestations, those measuring less than 2 cm in diameter, and when initial hCG concentrations are relatively high (49).

### UNUSUAL ECTOPIC PREGNANCIES

Extratubal ectopic pregnancies make up less than 10% of all ectopic pregnancies but are associated with greater morbidity (50). Surgery often is the most appropriate first-line treatment in such cases, but multiple-dose MTX also has been used effectively.

### Heterotopic Pregnancy

Heterotopic pregnancy is defined by coexisting intrauterine and extrauterine pregnancies. Approximately 1% of pregnancies resulting from assisted reproduction are heterotopic preg-

nancies. Unfortunately, approximately 50% of heterotopic pregnancies present with symptoms of acute rupture. Surgery usually is required, and MTX is contraindicated (51, 52).

### Interstitial Pregnancy

Interstitial, or cornual, pregnancies are highly morbid, with 2.2% maternal mortality. Approximately 4.7% of ectopic pregnancies implant in the interstitial segment of the tube. Such pregnancies generally are associated with very high serum hCG levels. The estimated success rate for medical treatment of interstitial pregnancy is lower than that for treatment of ectopic pregnancies located in the tubal ampulla or isthmus (53). When the embryo exhibits cardiac activity, direct injection of potassium chloride into the embryo or fetus has been suggested as an adjunct to systemic MTX treatment that may help to prevent further growth and development. Emergency hysterectomy sometimes is required (54).

### Cervical Pregnancy

Cervical pregnancies are rare. Ultrasonography is the most useful diagnostic tool. Systemic MTX or uterine artery embolization have been used successfully to treat cervical pregnancy. In the presence of cardiac activity, cervical pregnancies also have been successfully treated with direct injection of potassium chloride or MTX (55, 56).

### Ovarian and Abdominal Pregnancies

Ovarian and abdominal pregnancies are diagnosed definitively at the time of surgical exploration. Therefore, MTX is not a first-line treatment for these conditions but may have been initiated if diagnosed incorrectly as tubal pregnancies.

### Cesarean Scar Pregnancies

Ectopic gestation at the site of a cesarean section scar is uncommon but can result in uterine rupture and hemorrhage (57). The diagnosis is confirmed via ultrasonographic examination showing a gestational sac in the myometrium of the anterior lower uterine segment. Surgical treatment options include dilation and curettage and trophoblastic excision via either laparotomy or laparoscopy. There are several case reports of the successful management of cesarean scar ectopic pregnancies via the systemic and/or local administration of MTX with and without subsequent dilation and curettage (58, 59).

### Fertility after Medical Treatment of Ectopic Pregnancy

There is no evidence to suggest an adverse effect of MTX therapy for ectopic pregnancy on subsequent fertility or ovarian reserve (60, 61). A recent observational population-based study of 1,064 women described 24-month cumulative intrauterine pregnancy rates of 67%, 76%, and 76% after salpingectomy, salpingostomy, and medical treatment, respectively (62).

**TABLE 6**

Treatment and drug side effects associated with MTX (25–27, 35, 42–44).

Treatment side effects	Drug side effects
<ul style="list-style-type: none"> <li>• Increase in abdominal girth</li> <li>• Increase in hCG during initial therapy</li> <li>• Vaginal bleeding or spotting</li> <li>• Abdominal pain</li> </ul>	<ul style="list-style-type: none"> <li>• Gastric distress, nausea, and vomiting</li> <li>• Stomatitis</li> <li>• Dizziness</li> <li>• Severe neutropenia (rare)</li> <li>• Reversible alopecia (rare)</li> <li>• Pneumonitis (rare)</li> </ul>

Note: MTX = methotrexate.

Practice Committee. Medical treatment of ectopic pregnancy. *Fertil Steril* 2013.

## COST ANALYSIS

Approximately 40% of women diagnosed with an ectopic pregnancy are candidates for medical management (35), and 90% of those can be treated successfully without surgery (30, 31). Whereas the costs of surgery and outpatient medical management vary widely with the treating facility and the region of the country, many cost-effectiveness analyses have favored MTX therapy. Because medical treatments can be administered in an office setting, MTX is less expensive than surgery. Primary surgical therapy is favored when the likelihood of failure or morbidity from medical treatment is high and when the time to resolution likely is to be prolonged. Such cases generally are characterized by high initial hCG levels and/or the presence of embryonic cardiac activity (63, 64).

## SUMMARY

- Most ectopic pregnancies can be diagnosed at early stages, even before symptoms become evident.
- Serial serum hCG determinations, transvaginal ultrasound examinations, and uterine curettage provide the means for early diagnosis.
- Success rates and fertility after treatment are comparable for medical therapy and conservative surgical treatment.
- Methotrexate-induced embryopathy is a serious and avoidable complication that may arise when a viable pregnancy is misdiagnosed as an ectopic pregnancy and exposed to MTX treatment.

## CONCLUSIONS

- Both conservative surgery and medical therapy may be viewed as appropriate first-line therapies in many early unruptured ectopic pregnancies.
- Multiple-dose MTX treatment has a lower failure rate than single-dose MTX. Single-dose MTX is sufficient to treat persistent trophoblastic tissue after salpingostomy and ectopic pregnancies associated with low initial hCG values.
- Postoperative, prophylactic, single-dose systemic MTX may reduce the incidence of persistent ectopic pregnancy after salpingostomy.
- Medical therapy appears more cost-effective than surgery except when the initial hCG level is high and/or embryonic cardiac activity is observed.

**Acknowledgments:** This report was developed under the direction of the Practice Committee of the American Society for Reproductive Medicine as a service to its members and other practicing clinicians. Although this document reflects appropriate management of a problem encountered in the practice of reproductive medicine, it is not intended to be the only approved standard of practice or to dictate an exclusive course of treatment. Other plans of management may be appropriate, taking into account the needs of the individual patient, available resources, and institutional or clinical practice limitations. The Practice Committee and the Board of Directors of the American Society for Reproductive Medicine have approved this report.

This document was reviewed by ASRM members, and their input was considered in the preparation of the final document. The following members of the ASRM Practice Committee participated in the development of this document. All Committee members disclosed commercial and financial relationships with manufacturers or distributors of goods or services used to treat patients. Members of the Committee who were found to have conflicts of interest based on the relationships disclosed did not participate in the discussion or development of this document.

Samantha Pfeifer, M.D.; Jeffrey Goldberg, M.D.; Roger Lobo, M.D.; Michael Thomas, M.D.; Eric Widra, M.D.; Mark Licht, M.D.; John Collins, M.D.; Marcelle Cedars, M.D.; Michael Vernon, Ph.D.; Daniel Dumesic, M.D.; Randall Odem, M.D.; Margareta Pisarska, M.D.; Jay Sandlow, M.D.; Mitchell Rosen, M.D.; Owen Davis, M.D.; Clarisa Gracia, M.D., M.S.C.E.; William Catherino, M.D., Ph.D.; Kim Thornton, M.D.; Robert Rebar, M.D.; Andrew La Barbera, Ph.D.

## REFERENCES

1. Berg CJ, Chang J, Callaghan WM, Whitehead SJ. Pregnancy-related mortality in the United States, 1991–1997. *Obstet Gynecol* 2003;101:289–96.
2. Hajenius PJ, Engelsbel S, Mol BW, Van der Veen F, Ankum WM, Bossuyt PM, et al. Randomised trial of systemic methotrexate versus laparoscopic salpingostomy in tubal pregnancy. *Lancet* 1997;350:774–9.
3. Centers for Disease Control and Prevention (CDC). Ectopic pregnancy—United States, 1990–1992. *MMWR Morb Mortal Wkly Rep* 1995;44:46–8.
4. Zane SB, Kieke BA Jr, Kendrick JS, Bruce C. Surveillance in a time of changing health care practices: estimating ectopic pregnancy incidence in the United States. *Matern Child Health J* 2002;6:227–36.
5. Wong JA, Clark JF. Correlation of symptoms with age and location of gestation in tubal pregnancy. *J Natl Med Assoc* 1968;60:221–3.
6. Ankum WM, Mol BW, Van der Veen F, Bossuyt PM. Risk factors for ectopic pregnancy: a meta-analysis. *Fertil Steril* 1996;65:1093–9.
7. Saraiya M, Berg CJ, Kendrick JS, Strauss LT, Atrash HK, Ahn YW. Cigarette smoking as a risk factor for ectopic pregnancy. *Am J Obstet Gynecol* 1998;178:493–8.
8. Butts S, Sammel M, Hummel A, Chittams J, Barnhart K. Risk factors and clinical features of recurrent ectopic pregnancy: a case control study. *Fertil Steril* 2003;80:1340–4.
9. Stovall TG, Ling FW, Carson SA, Buster JE. Nonsurgical diagnosis and treatment of tubal pregnancy. *Fertil Steril* 1990;54:537–8.
10. Barnhart K, Mennuti MT, Benjamin I, Jacobson S, Goodman D, Coutifaris C. Prompt diagnosis of ectopic pregnancy in an emergency department setting. *Obstet Gynecol* 1994;84:1010–5.
11. Gracia CR, Barnhart KT. Diagnosing ectopic pregnancy: decision analysis comparing six strategies. *Obstet Gynecol* 2001;97:464–70.
12. Fritz MA, Guo SM. Doubling time of human chorionic gonadotropin (hCG) in early normal pregnancy: relationship to hCG concentration and gestational age. *Fertil Steril* 1987;47:584–9.
13. Timor-Tritsch IE, Yeh MN, Peisner DB, Lesser KB, Slavik TA. The use of transvaginal ultrasonography in the diagnosis of ectopic pregnancy. *Am J Obstet Gynecol* 1989;161:157–61.
14. Romero R, Kadar N, Copel JA, Jeanty P, DeCherney AH, Hobbins JC. The value of serial human chorionic gonadotropin testing as a diagnostic tool in ectopic pregnancy. *Am J Obstet Gynecol* 1986;155:392–4.
15. Kadar N, Romero R. Observations on the log human chorionic gonadotropin-time relationship in early pregnancy and its practical implications. *Am J Obstet Gynecol* 1987;157:73–8.
16. Barnhart KT, Sammel MD, Rinaudo PF, Zhou L, Hummel AC, Guo W. Symptomatic patients with an early viable intrauterine pregnancy: hCG curves redefined. *Obstet Gynecol* 2004;104:50–5.

17. Chung K, Sammel MD, Chalian R, Coutifaris C, Feedman M, Barnhart KT. Defining the rise of serum HCG in viable pregnancies achieved through use of IVF. *Hum Reprod* 2006;213:823–8.
18. Kadar N, Freedman M, Zacher M. Further observations on the doubling time of human chorionic gonadotropin in early asymptomatic pregnancies. *Fertil Steril* 1990;54:783–7.
19. Barnhart K, Sammel MD, Chung K, Zhou L, Hummel AC, Guo W. Decline of serum human chorionic gonadotropin and spontaneous complete abortion: defining the normal curve. *Obstet Gynecol* 2004;104:975–81.
20. Barnhart KT, Katz I, Hummel A, Gracia CR. Presumed diagnosis of ectopic pregnancy. *Obstet Gynecol* 2002;100:505–10.
21. Barnhart KT, Gracia CR, Reindl B, Wheeler JE. Usefulness of pipelle endometrial biopsy in the diagnosis of women at risk for ectopic pregnancy. *Am J Obstet Gynecol* 2003;188:906–9.
22. Ries A, Singson P, Bidus M, Barnes JG. Use of the endometrial pipelle in the diagnosis of early abnormal gestations. *Fertil Steril* 2000;74:593–5.
23. Ailawadi M, Lorch SA, Barnhart KT. Cost-effectiveness of presumptively medically treating women at risk for ectopic pregnancy compared with first performing a dilatation and curettage. *Fertil Steril* 2005;83:376–82.
24. Adam MP, Manning MA, Beck AE, Kwan A, Enns GM, Clericuzio C, et al. Methotrexate/misoprostol embryopathy: report of four cases resulting from failed medical abortion. *Am J Med Genet A* 2003;123:72–8.
25. Berlin NI, Rall D, Mead JA, Freireich EJ, Vanscott E, Hertz R, et al. Folic acid antagonists: effects on the cell and the patient: combined clinical staff conference at the National Institutes of Health. *Ann Intern Med* 1963;59:931–56.
26. Calabresi P, Chabner BA. Antineoplastic agents. In: Gilman A, Goodman LS, Goodman A, editors. *The pharmacologic basis of therapeutics*. 8th ed. New York: Macmillan; 1990:1275–6.
27. Rodi IA, Sauer MV, Gorrill MJ, Bustillo M, Gunning JE, Marshall JR, et al. The medical treatment of unruptured ectopic pregnancy with methotrexate and citrovorum rescue: preliminary experience. *Fertil Steril* 1986;46:811–3.
28. Ory SJ, Villanueva AL, Sand PK, Tamura RK. Conservative treatment of ectopic pregnancy with methotrexate. *Am J Obstet Gynecol* 1986;154:1299–306.
29. Stovall TG, Ling FW, Buster JE. Outpatient chemotherapy of unruptured ectopic pregnancy. *Fertil Steril* 1989;51:435–8.
30. Pisarska MD, Carson SA, Buster JE. Ectopic pregnancy. *Lancet* 1998;351:1115–20.
31. Lipscomb GH, Stovall TG, Ling FW. Nonsurgical treatment of ectopic pregnancy. *N Engl J Med* 2000;343:1325–9.
32. Barnhart K, Coutifaris C, Esposito M. The pharmacology of methotrexate. *Expert Opin Pharmacother* 2001;2:409–17.
33. Stovall TG, Ling FW, Gray LA. Single-dose methotrexate for treatment of ectopic pregnancy. *Obstet Gynecol* 1991;77:754–7.
34. Lipscomb GH, Bran D, McCord ML, Portera JC, Ling FW. Analysis of three hundred fifteen ectopic pregnancies treated with single-dose methotrexate. *Am J Obstet Gynecol* 1998;178:1354–8.
35. Barnhart KT, Gosman G, Ashby R, Sammel M. The medical management of ectopic pregnancy: a meta-analysis comparing "single dose and multidose" regimens. *Obstet Gynecol* 2003;101:778–84.
36. Alleyassin A, Khademi A, Aghahosseini M, Safdarian L, Badenoosh B, Hamed EA. Comparison of success rates in the medical management of ectopic pregnancy with single-dose and multiple-dose administration of methotrexate: a prospective, randomized clinical trial. *Fertil Steril* 2006;85:1661–6.
37. Barnhart KT, Sammel MD, Hummel A, Jain J, Chakhtoura N, Strauss J. A novel "two dose" regimen of methotrexate to treat ectopic pregnancy [abstract]. *Fertil Steril* 2005;84(Suppl):S130.
38. Barnhart K, Hummel AC, Sammel MD, Menon S, Jain J, Chakhtoura N. Use of "2-dose" regimen of methotrexate to treat ectopic pregnancy. *Fertil Steril* 2007;87:250–6.
39. Tawfiq A, Agameya AF, Claman P. Predictors of treatment failure for ectopic pregnancy treated with single-dose methotrexate. *Fertil Steril* 2000;74:877–80.
40. Potter MB, Lepine LA, Jamieson DJ. Predictors of success with methotrexate treatment of tubal ectopic pregnancy at Grady Memorial Hospital. *Am J Obstet Gynecol* 2003;188:1192–4.
41. Elito J Jr, Reichmann AP, Uchiyama MN, Camano L. Predictive score for the systemic treatment of unruptured ectopic pregnancy with a single dose of methotrexate. *Int J Gynaecol Obstet* 1999;67:75–9.
42. Lipscomb GH, McCord ML, Stovall TG, Huff G, Portera SG, Ling FW. Predictors of success of methotrexate treatment in women with tubal ectopic pregnancies. *N Engl J Med* 1999;341:1974–8.
43. Schoenfeld A, Mashiach R, Vardy M, Ovadia J. Methotrexate pneumonitis in nonsurgical treatment of ectopic pregnancy. *Obstet Gynecol* 1992;80:520–1.
44. Isaacs JD, McGehee RP, Cowan BD. Life-threatening neutropenia following methotrexate treatment of ectopic pregnancy: a report of two cases. *Obstet Gynecol* 1996;88:694–6.
45. Lipscomb GH, Puckett KJ, Bran D, Ling FW. Management of separation pain after single-dose methotrexate therapy for ectopic pregnancy. *Obstet Gynecol* 1999;93:590–3.
46. Dudley P, Heard MJ, Sangi-Hagheykar H, Carson SA, Buster JE. Characterizing ectopic pregnancies that rupture despite treatment with methotrexate. *Fertil Steril* 2004;82:1374–8.
47. Atri M, Bret PM, Tulandi T, Senterman MK. Ectopic pregnancy: evolution after treatment with transvaginal methotrexate. *Radiology* 1992;185:749–53.
48. Graczykowski JW, Mishell DR Jr. Methotrexate prophylaxis for persistent ectopic pregnancy after conservative treatment by salpingostomy. *Obstet Gynecol* 1997;89:118–22.
49. Gracia CR, Brown HA, Barnhart KT. Prophylactic methotrexate after linear salpingostomy: a decision analysis. *Fertil Steril* 2001;76:1191–5.
50. Jourdain O, Fontanges M, Schiano A, Rauch F, Gonnet JM. Management of other ectopic pregnancies (cornual, interstitial, angular, ovarian). *J Gynecol Obstet Biol Reprod (Paris)* 2003;32:S93–100.
51. Chin HY, Chen FP, Wang CJ, Shui LT, Liu YH, Soong YK. Heterotopic pregnancy after in vitro fertilization-embryo transfer. *Int J Gynaecol Obstet* 2004;86:411–6.
52. Fernandez H, Gervaise A. Ectopic pregnancies after infertility treatment: modern diagnosis and therapeutic strategy. *Hum Reprod Update* 2004;10:503–13.
53. Barnhart K, Spandorfer S, Coutifaris C. Medical treatment of interstitial pregnancy: a report of three unsuccessful cases. *J Reprod Med* 1997;42:521–4.
54. Tulandi T, Al-Jaroudi D. Interstitial pregnancy: results generated from the Society of Reproductive Surgeons Registry. *Obstet Gynecol* 2004;103:47–50.
55. Cepni I, Ocal P, Erkan S, Erzik B. Conservative treatment of cervical ectopic pregnancy with transvaginal ultrasound-guided aspiration and single-dose methotrexate. *Fertil Steril* 2004;81:1130–2.
56. Ushakov FB, Elchalal U, Aceman PJ, Schenker JG. Cervical pregnancy: past and future. *Obstet Gynecol Surv* 1997;52:45–59.
57. Herman A, Weinraub Z, Avrech O, Maymon R, Ron-El R, Bukovsky Y. Follow up and outcome of isthmic pregnancy located in a previous cesarean section scar. *Br J Obstet Gynecol* 1995;102:839–41.
58. Muraji M, Mabuchi S, Hisamoto K, Muranishi M, Kanagawa T, Kimura T. Cesarean scar pregnancies successfully treated with methotrexate. *Acta Obstet Gynecol Scand* 2009;88:720–3.
59. Fadhlouai A, Khrouf M, Khemiri K, Nouira K, Chaker A, Zhioua F. Successful conservative treatment of a cesarean scar pregnancy with systemically administered methotrexate and subsequent dilation and curettage: a case report. *Case Rep Obstet Gynecol* 2012;2012:248564.
60. Keefe KA, Wald JS, Goldstein DP, Bernstein M, Berkowitz RS. Reproductive outcome after methotrexate treatment of tubal pregnancies. *J Reprod Med* 1998;43:28–32.
61. Oriol B, Barrio A, Pacheco A, Serna J, Zuzuarregui JL, Garcia-Velasco JA. Systemic methotrexate to treat ectopic pregnancy does not affect ovarian reserve. *Fertil Steril* 2008;90:1579–82.
62. de Bennetot M, Rabischong B, Aublet-Cuvelier B, Belard F, Fernandez H, Bouyer J, et al. Fertility after tubal ectopic pregnancy: results of a population-based study. *Fertil Steril* 2012;98:1271–6.
63. Morlock RJ, Lafata JE, Eisenstein D. Cost-effectiveness of single-dose methotrexate compared with laparoscopic treatment of ectopic pregnancy. *Obstet Gynecol* 2000;95:407–12.
64. Sowter MC, Farquhar CM, Gudex G. An economic evaluation of single dose systemic methotrexate and laparoscopic surgery for the treatment of unruptured ectopic pregnancy. *BJOG* 2001;108:204–12.